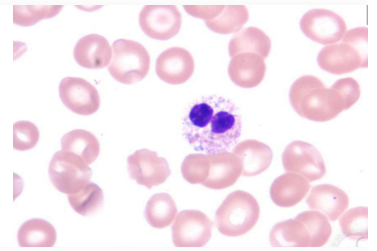




Cell Morphology by PAS

4 plays • 12 players

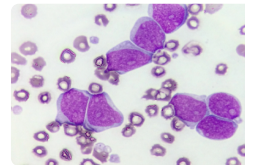
A public kahoot



Questions (10)

1 - Quiz

Question 1. What is it?



Lymphocyte



Monocyte



Myeloblast

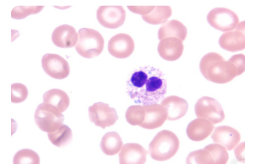


Smudgy cell



2 - Quiz

Question 2. What is it?



Neutrophil



Neutrophil Hypersegmented



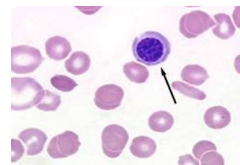
Pelger –Huet anomaly



Band Form



3 - Quiz

Question 3. What is it?

Spherocyte



Lymphoblast



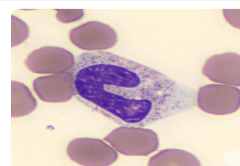
Nucleated RBC



Lymphocyte



4 - Quiz

Question 4. What is it?

Monocyte



Band form



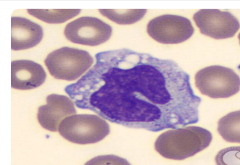
Blast cell



Neutrophil



5 - Quiz

Question 5. What is it?

Monocyte



Myeloblasts



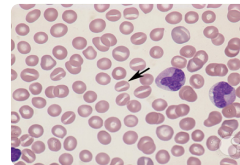
Metamyelocyte



Atypical Lymphocyte



6 - Quiz

Question 6. What is it?

Normal RBC



Spherocyte



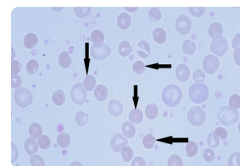
Stomatocyte



Elliptocyte



7 - Quiz

Question 7. What is it?

Stomatocyte



Normal RBC



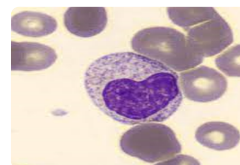
Elliptocyte



Spherocyte



8 - Quiz

Question 8. What is it?

Monocyte



Myeloblasts



Metamyelocyte

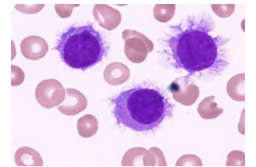


Atypical Lymphocyte



9 - Quiz

Question 9. What is it?



Lymphocyte



Basket cell



Smudge cell

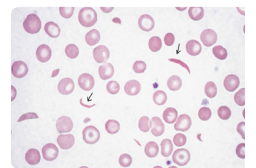


Hairy cell



10 - Quiz

Question 10. What is it?



Sickle cell



Spherocyte



Elliptocyte



Schistocyte



Resource credits ^